

# Periodontal Diseases Diagnosed Automatically Using Image Processing Techniques.

Darshan Tajne, Kundlik Bhope, Shraddha Jadhav, Komal Kahandal

Department of Computer Technology Shatabdi Institute College of Engineering (Pune University) Nasik, India

## ABSTRACT

Dental radiographs are an important tool for diagnosing periodontal disorders and assessing treatment outcomes. Radiography will become even more important in periodontal diagnosis as computer-based image acquisition and processing techniques improve. To identify periodontal diseases, Digital Subtraction Radiography (DSR) requires a pair of images with identical gray-level distribution and projection geometry. Without mechanical alignment of the patient, film, or x-ray source, a pair of identical images can be generated via DSR. The disadvantage of this technique is that if there is any mechanical alignment in the camera view, the outcome will be mismatched. This research describes a method for diagnosing periodontal disorders utilising a single radiographic X-ray image, eliminating the need for two scans.

## I. INTRODUCTION

Gums or gingiva support the teeth. Periodontal ligaments connect a tooth's root to its socket. Periodontal diseases are dangerous bacterial infections that wreak havoc on the mouth's gums and surrounding tissues. Periodontal disorders impact the gums, the bone surrounding the tooth, and the tooth's membrane. "Gum Recession" is another name for the Gum Eroded Region. Gum recession occurs when the protective tissue around the teeth begins to deteriorate. The base of the tooth erodes, exposing the tooth's root. Gum recession, if left unchecked, can lead to tooth loss. sensitivity, as well as increased gum and bone loss. Gum recession can be caused by two factors. I Tooth-Brushing Procedures (ii). Periodontal Diseases are a group of diseases that affect the gums and teeth. Gum disease is a common cause of receding gums. When you have gum disease, Plaque and tartar build up at the gum line, causing irritation. If left untreated, the gums pull away from the teeth, leaving pockets that are deep, bacteria-filled crevices. In medicine and dentistry, the direct and indirect digital imaging systems have resulted in a wide range of computer-based diagnostic imaging technologies. Image enhancement, processing, and visualisation are examples of such uses in clinical diagnosis. Enhancement of images Algorithms provide a wide range of options for changing diagnostic pictures to provide visually appealing results. The task, image content, observer characteristics, and viewing conditions all influence which strategies are used. conditions. The paper focuses on spatial domain approaches that alter the image data array directly. either either point or area processing or processing by area There are two types of point processing. Point processing, both linear and non-linear. Gray levels can be changed in an endless number of nonlinear ways fashion. Gray level slicing, lookup table method, and histogram are all examples of exponential and logarithmic intensity adjustments modification. The most commonly utilised method among these is histogram modification. The disadvantage of this approach is that they may result in image quality degradation in specific areas and increased noise visibility. Subtraction radiography based on digital imaging can easily reveal temporal changes in lesion images. A pair of photos with the same gray-level distribution and projection geometry are required for this operation. The grayscale distribution and viewpoint Images can be rectified through projection. processing of digital images A pair of Without mechanical alignment of the patient, film, and x-ray source, identical pictures can be obtained .

## II. LITERATURE SURVEY

### 1. Automated Diagnosis of Periodontal Diseases Using Image Processing Techniques

Dental Radio-graphs have a valuable aid in the diagnosis of periodontal diseases and the evaluation of treatment effects. Computer-based image acquisition and processing techniques will now further increase the importance of radiography in periodontal diagnosis. Digital Subtraction Radiography (DSR) requires a pair of images with identical gray-level distribution and projection geometry is needed to identify the periodontal diseases. In DSR, a pair of identical images can be obtained without mechanical alignment of patient, film and x-ray source. The drawback of this technique is, if there is any mechanical alignment in the camera view then mismatching will occur in the result. This paper presents a method for automated diagnosis of periodontal diseases using a single radiographic X-ray image which eliminates the requirement of pair of images.

### 2. Image Inpainting

Authors: Marcelo Bertolami, Guillermo Shapiro, Vicent Casellis and Coloma Baluster. Inpainting, the technique of modifying an image in an undetectable form, is as ancient as art itself. The goals and applications of inpainting are numerous, from the restoration of damaged paintings and photographs to the removal/replacement of selected objects. In this paper, we introduce a novel algorithm for digital inpainting of still images that attempts to replicate the basic techniques used by professional

## III. PROBLEM STATEMENT

### 3.1 Problem Statement

To design and develop a system of image processing for prognosticating the consequences of periodontal disease. Methods of analysing and foretelling the effects of the disease through pictorial depiction is not yet into existence. Hence, the traditional method of just warning the patient of the future consequence is not elective as it is supposed to be which delays the treatment causing distortion and mobility in teeth.

### 3.2 Objectives

To speculate the state of the dentition which may be suffering from periodontal disease. To help the medical practitioners to explain the patient about the consequences of the disease more accurately.

## IV. PROJECT REQUIREMENTS

### 4.1 Proposed System

To design and develop a system of image processing for prognosticating the consequences of periodontal disease. Methods of analyzing and foretelling the effects of the disease through pictorial depiction is not yet into existence. Hence, the traditional method of just warning the patient of the future consequence is not effective as it is supposed to be which delays the treatment causing distortion and mobility in teeth. Periodontitis is an "infections" disease affecting teeth and surrounding structures such as gums and bone which holds the teeth in position.

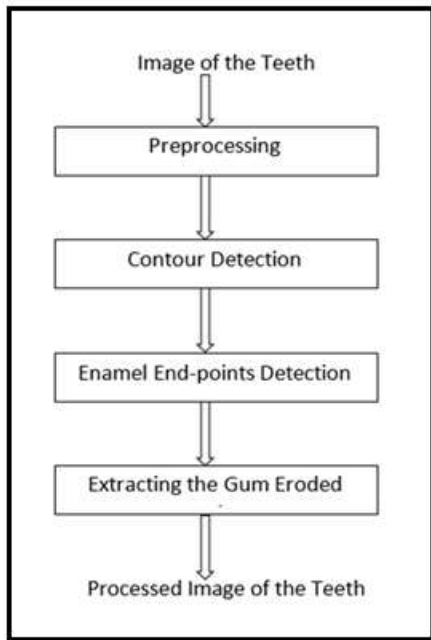


Figure 3.1: Proposed architecture

### V. RESULTS AND DISUSSIONS

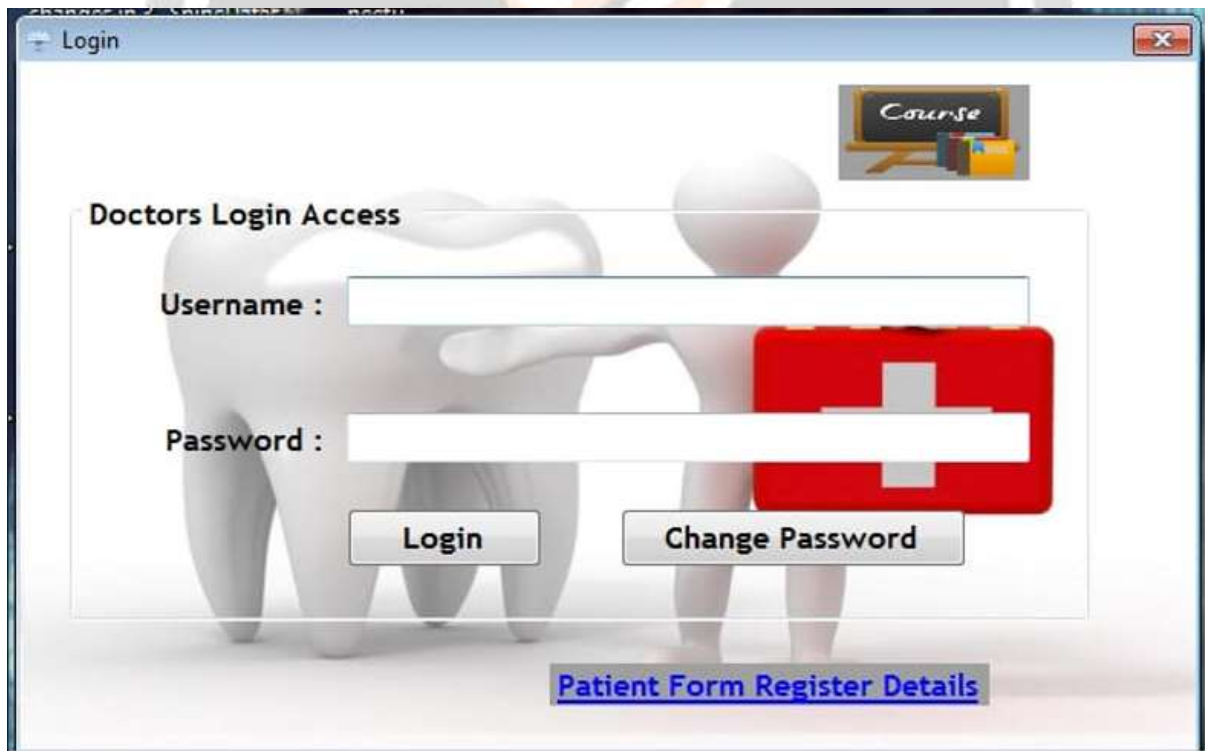


Fig 3.1 Login Window

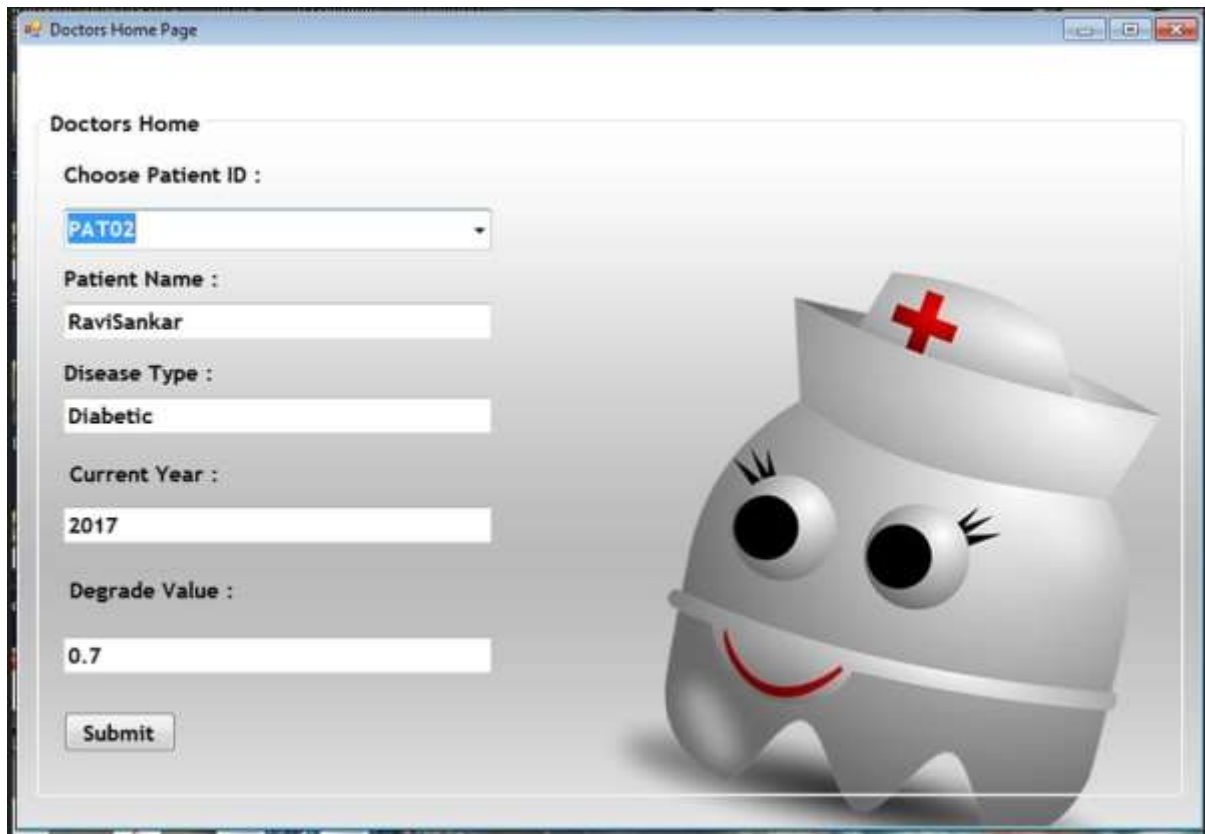


Fig 3.2. Doctor Home Page.

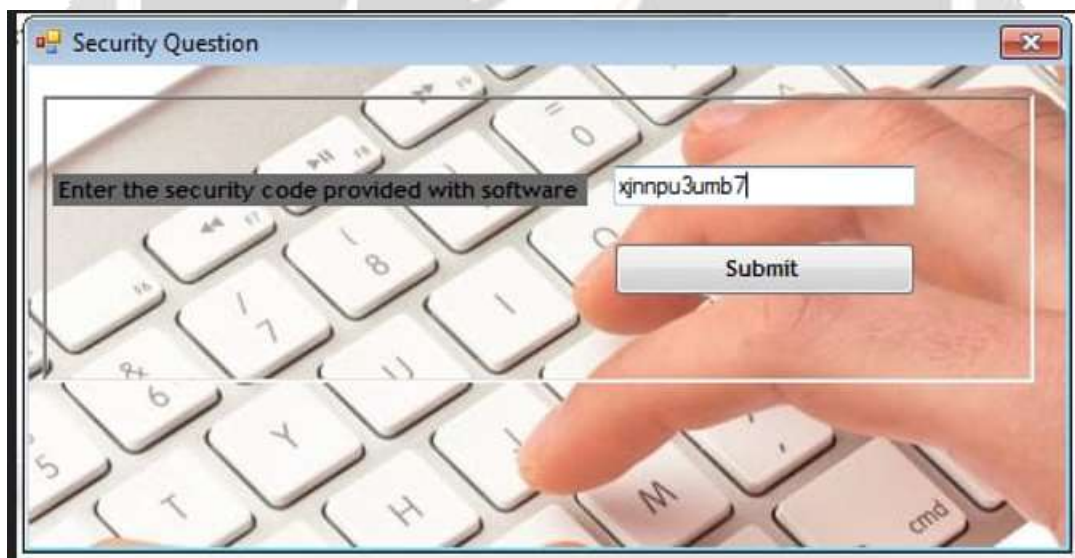


Fig 3.3 Security Window.

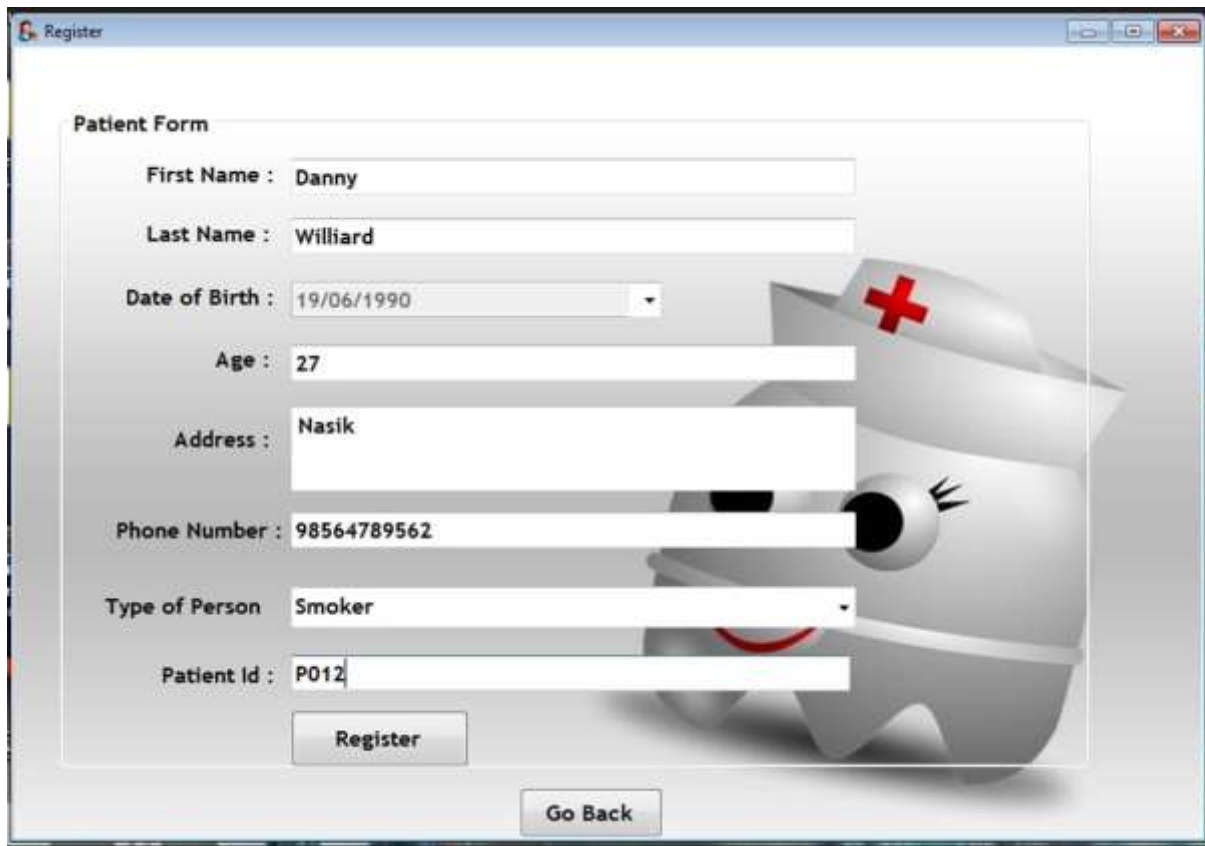


Fig 3.4 Register Window Form.

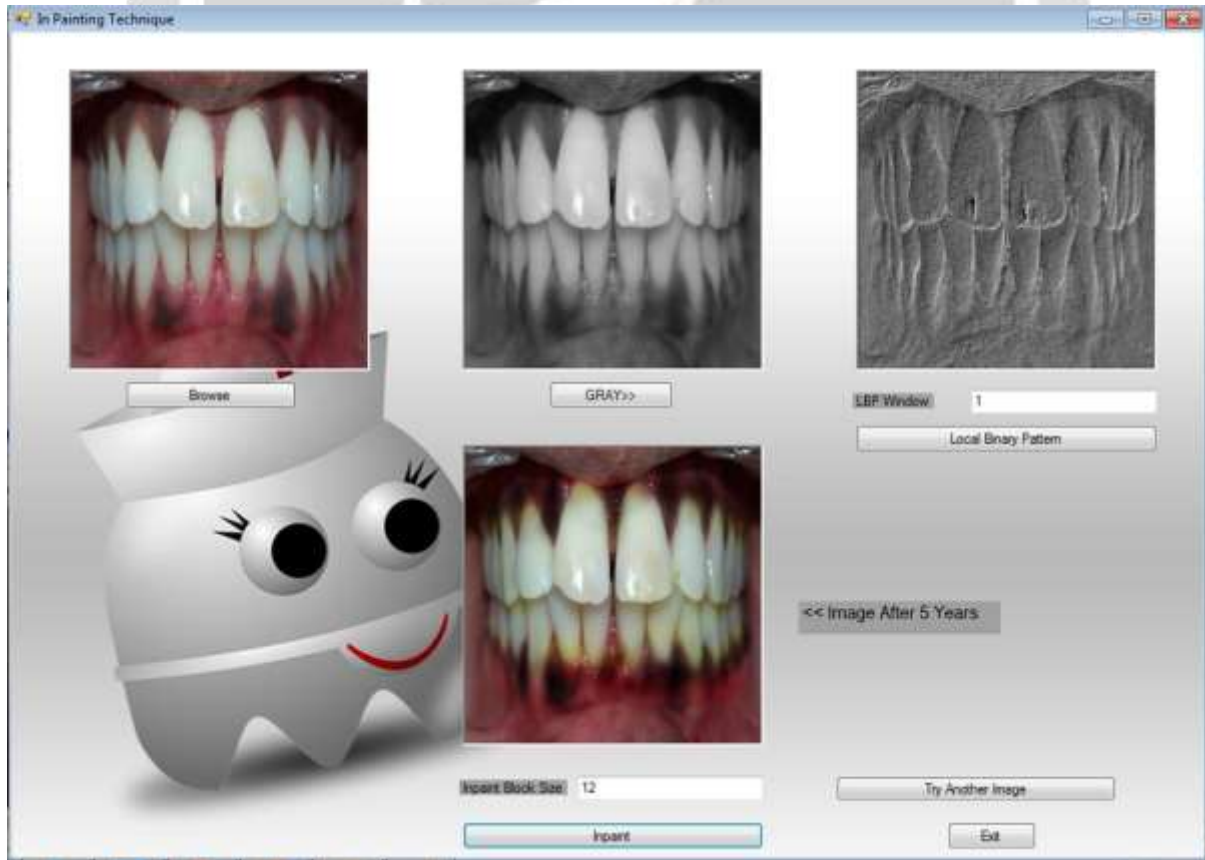


Fig 3.5 Painting Methodology.

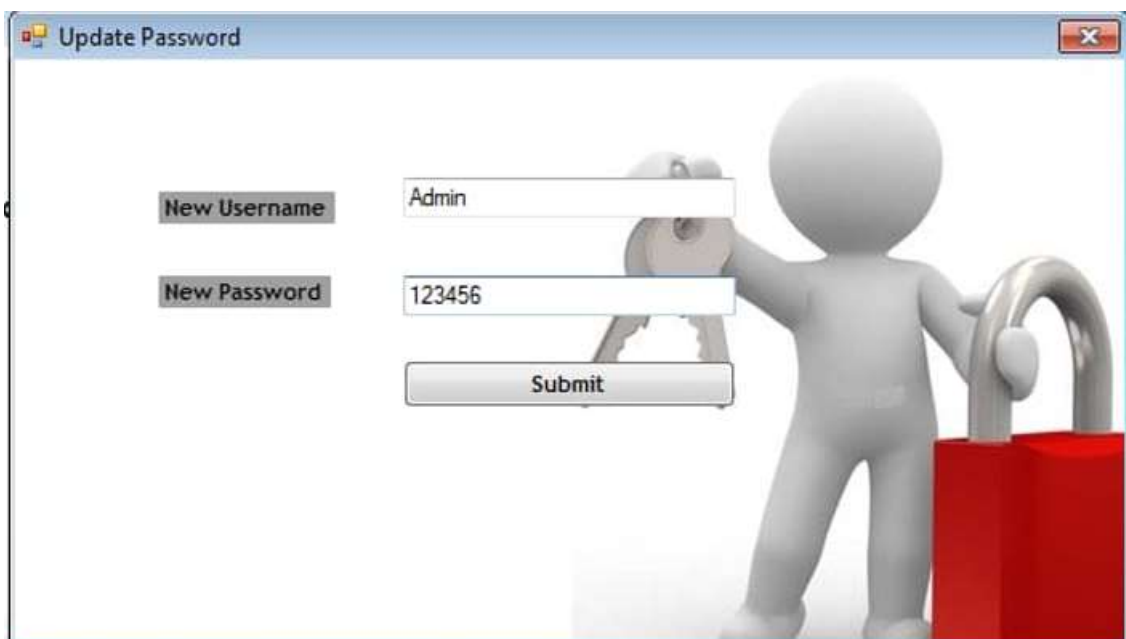

Fig. 3.6 New User Login Window.

The input images is process in our system, first Gray scale is applied after that LPB method is applied to find the proper edges and as the last the inpainting method is applied to show how the teeth looks after 5 years.

## VI. CONCLUSION

A visual aid can be generated showing the possible progression of disease, a lot of dental morbidity and mortality can be avoided. It will help patients to understand the treatment plan and help doctor to manage the problem at a very early stage. Here, the perspective of projection of images is corrected by means of digital image processing. Predetermination of the damages to the tooth and the gums helps it to recover at early stage and make people realize that they need a treatment. A visual aid can be generated showing the possible progression of disease, a lot of dental morbidity and mortality can be avoided.

## VII. REFERENCES

- [1] M.Thamarai, M.Kalpna "Automated Diagnosis of Periodontal Diseases Using Image Processing Techniques" International Journal of Innovative Research in Science, Engineering and Technology
- [2] Marcelo Bertalmio and Guillermo Sapiro "Image Inpainting"
- [3] M.Analoui, "Radiographic Image Enhancement using Spatial Domain Techniques", Dentomaxillofacial Radiology (2001).
- [4] E.Hekmatiana DDS, S.Shari\_ DDS, N.Khodaian DDS, "Literature Review Digital Subtraction Radiography in Dentistry", (2008).
- [5] Mr. Anjan Bikash Maity, Mr. Sandip Mandal, Mr. Ranjan Podder, "Edge Detection Using Morphological Method and Corner Detection. Using Chain Code Algorithm", International Journal of Computer Science Issues, Vol. 8, Issue 4, No 1, July 2011.
- [6] Roli Bansal, Priti Sehgal & Punam Bedi "Effective Morphological Extraction of True Fingerprint Minutiae based on the Hit or Miss Transform", International journal of Biometrics and Bioinformatics(IJBB), Volume (4) : Issue (2), July 2009.
- [7] E. Hastings, "A Survey of Thinning Methodologies", Pattern analysis and Machine Intelligence, IEEE Transactions, vol. 4, Issue 9, pp. 869-885, 1992.
- [8] Manvjeet Kaur, Mukhwinder Singh, Akshay Girdhar, and Parvinder S. Sandhu, "Fingerprint Verification using Minutiae Extraction Technique", World Academy of Science, Engineering and Technology 2008
- [9] Philippe Parra, "Fingerprint minutiae extraction and matching for identification procedure".